



शरीरमाद्यं खलु धर्मसाधनम्

एकक/Unit _____

विभाग/Dept. _____

नाम/N

अ० भा० आ० सं० अस्पताल/A.I.I.M.S. HOSPITAL बहिरंग रोगी विभाग /Out Patient Department

अस्पताल के अन्दर धूम्रपान करना है।/SMOKING IS PROHIBITED IN HOSPITAL PREMISES



बाल चिकित्सा विभाग.
UHID:108060720



Dept No: 20250030001761
Clinic No: 2025/POC/31

NITIKA

कमरा / Room
C-209

Queue / संख्या
F15

Unit-I, POC,

OPR-6

सं/O.P.D. Regn. No. _____

D/O SAJJAN
2Y 3M 16D / F(महिला)
KUSMAURI, PIPRA MARORA, LAKHIMPUR
KHERI,UTTAR PRADESH Pin:261506
Ph: 9994346247 General Rs. 0
Follow Up Patient

सोम



Reporting: 03:20:33
03/02/2025

पता/Address

31/25

निदान/Diagnosis

दिनांक/Date

उपचार/Treatment

15
10/16/25

N/v

8/2/25

CBC/PH/UR

Signature

Trulyhelp Verify



प्रधानमंत्री जन आरोग्य योजना
(pmjay.gov.in)

CLEAN AND GREEN AIIMS / एम्स का यही संकल्प, स्वच्छता से काया कल्प
अंगदान-जीवन का बहुमूल्य उपहार/ORGAN DONATION - A GIFT OF LIFE
O.R.B.O., AIIMS, 26588360, 26593444, www.orbo.org Helpline - 1060 (24 hrs service)

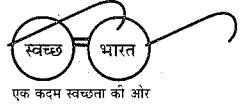

मेरा अस्पताल
My Hospital
meraaspatal.nhp.gov

T-572



अ० भा० आ० सं० अस्पताल/A.I.I.M.S. HOSPITAL
बहिरंग रोगी विभाग / Out Patient Department



अस्पताल के अन्दर धूम्रपान मना है।/SMOKING IS PROHIBITED IN HOSPITAL PREMISES

बाल चिकित्सा विभाग.

UHID:108060720

कमरा / Room
C-210

OPR-6



Dept No: 20250030001761

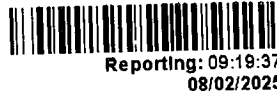Queue / संख्या
F97
Unit-III, Paediatric

ब०रो०वि० पंजीकृत सं०/O.P.D. Regn. No.

NITIKA

D/O SAJJAN
2Y 3M 21D / F/(महिला)
KUSMAJRI, PIPRA MARORA, LAKHIMPUR
KHERI, UTTAR PRADESH. Pin:261506.
Ph: 9994946247 General Rs. 0
Follow Up Patient

बुध,शनि, Wed,Sat



Reporting: 09:19:37
08/02/2025

आयु
Age

पता/Address

निदान/Diagnosis

दिनांक/Date

उपचार/Treatment

37
10-12

B/L EORB

Received first cycle HCV or 23/1 and 24/1.

- BMA/BMBx/CSF 31/1/25

PET scan - Date to be fixed.

HIV - pending

Advice:

Def 25/02/2025
27/01/25

1. To get PET date -

2. HIV Testing: Gate No.1 / etc

→ 3. To start Inj. G-CSF - from today

4. N/V are 1/2/25

5. Date for POC file 27/1/25 (Sister Tracy)

6. PTA - 6th floor RAK OPD.

7. Syp. Lactulose 10ML hs

Dr. Sanjana S
DM, Pediatric Oncology
AIIMS, New Delhi
DMC-100686



Pradhan Mantri Jan Arogya Yojana
Ayushman Bharat
PM-JAY
प्रधानमंत्री जन आरोग्य योजना
(pmjay.gov.in)

CLEAN AND GREEN AIIMS / एम्स का यही संकल्प, स्वच्छता से काया कल्प

अंगदान-जीवन का बहुमूल्य उपहार/ORGAN DONATION - A GIFT OF LIFE

O.R.B.O., AIIMS, 26588360, 26593444, www.orbo.org Helpline - 1060 (24 hrs service)



मेरा अस्पताल
My Hospital
meraaspatal.nhp.gov.in

S. PCT
Blood

बाल चिकित्सा विभाग
UHID: 108060720



Dept No: 20250030001761

TIKA

DR. SAJJAN
Y 3M 21D / F (महिला)

USMAURI, PIPRA MARORA, LAKHIMPUR
HERI, UTTAR PRADESH. Pin: 261506.

Ph: 9894946247 General Rs. 0

Follow Up Patient

कमरा / Room
C-210

Queue /
संख्या **F97**

Unit-III, Paediatric,

बुध, शनि, Wed, Sat



Reporting: 09:19:37
08/02/2025

24

10.15

N/V on 22/02/2025

Trulyhelp Verify

CBK / LFT / RET

Dr. Anil
Paediatric



अ० भा० आ० सं० अस्पताल / A.I.I.M.S. HOSPITAL
 बहिरंग रोगी विभाग / Out Patient Department



अस्पताल के अन्दर धूम्रपान मना है। / SMOKING IS PROHIBITED IN HOSPITAL PREMISES

बाल चिकित्सा विभाग

UHID: 108060720

कमरा / Room
C-210

OPR-6



Dept No: 20250030001761

Queue / संख्या
F97
Unit-III, Paediatric,

ब०रो०वि० पंजीकृत सं०/O.P.D. Regn. No.

NITIKA

D/O SAJJAN
 2Y 3M 21D / F/(महिला)
 KUSMAURI, PIPRA MARORA, LAKHIMPUR
 KHERI, UTTAR PRADESH. Pin: 261506.
 Ph: 9994946247 General Rs. 0
 Follow Up Patient

बुध, शनि, Wed, Sat



Reporting: 09:19:37
08/02/2025

प X	आयु Age	पता/Address

निदान/Diagnosis

दिनांक/Date	उपचार/Treatment
18/1/25	<p>Important note BIC ? cuts eye → 3 months 9 yr.</p> <p>↓</p> <p>Prognosis eye no (V) probably. headache headache.</p> <p>(V) accuracy to pain, no vision in both eyes.</p> <p>only 1 film and eye dilated local (V) on her family → ? (L) eye dilated local (V) on her part of orbit done would</p> <p>July to follow MRI brain / orbit repeat AB catheter near</p> <p>AB. gene seqing</p> <p>2 yrs</p> <p>NIV in OPD on 22/01/25 & CBV/NH/PG</p>



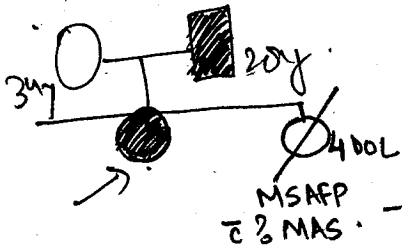
CLEAN AND GREEN AIIMS / एम्स का यही संकल्प, स्वच्छता/स्वच्छता कल्प
 अंगदान-जीवन का बहुमूल्य उपहार / ORGAN DONATION - A GIFT OF LIFE
 O.R.B.O., AIIMS, 26588360, 26593444, www.orbo.org Helpline - 1060 (24 hrs service)





S2

10 3/4



MSAFP
± MAS

- B/L white eye reflex :: 3mo of age
- Protrusion of left eye :: 2 weeks

- family history of Retinoblastoma in father
- EN done in childhood

- No h/o Vomiting / lethargy / Ab⊙ body movement
- No h/o weight loss / ↑ sed appetite

O/E: L/E: ⊙ eye Buphthalmos ⊕ ant
Proptosis ⊕ ant

No Pre/post auricular LN

Chest: B/L A/E ⊕ ant
No added sounds

CVS: ⊕ S1, S2 heard
No murmur

PIA: Soft, NT
No OM

USG Bscan: ⊕ Mass at post. pole
⊕ high spike - Calcification ⊕
⊕ whole globe filled mass
No IO contents distinguished
High spikes s/o calcification ⊕ ant

MRI Brain: → outside reports
NRC: ⊕ ON thickening ⊕ ant
pending ⊕ abutting ON

RC discussion:

↓
B/L EORB (B/L intraorbital part of ON involved)
optic chiasm → ⊕

Adv: .

- EUA. Pending
- RC discussion for ON involvement
- RB1 gene analysis
- cycle 1 HDCEV date from daycare
- N/V in PSC at 2PM on 23/01/2025

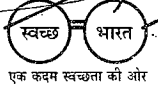
Shivani
SR/Peds onco



अ० भा० आ० सं० अस्पताल / A.I.I.M.S. HOSPITAL

बहिरंग रोगी विभाग / Out Patient Department

अस्पताल के अन्दर धूम्रपान मना है / SMOKING IS PROHIBITED IN HOSPITAL PREMISES



शरीरमाद्यं खलु धर्मसाधनम्

OPR-6

एकक/Unit T11
विभाग/Dept. Pediatrics

ब०रो०वि० पंजीकृत सं०/O.P.D. Regn. No. _____

नाम/Name	पिता/पुत्र/पत्नी/पुत्री F/S/W/D of	लिंग Sex	आयु Age	पता/Address
Balraj Singh	2y 3m / F			
108060720				

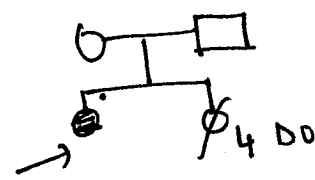
निदान/Diagnosis 212

Ashtivani
दिनांक/Date
To meet

उपचार/Treatment
do Bc EOP (L > R)

Rediscussion: (MRI)
↓
Bc EOP RB (Bc intra orbital)
agom involved
optic chiasm

family Hx of RB in father
EN → in childhood



US scan
↳ (B) mass @ post pole
↳ high spine calcification + w
↳ (D) whole globe filled w
mas.
No IO contents
deshingrashed
high spine slo
calcification + w

Truylhelp

Adv UD/w Prof. R. Sethi
- PET scan → date | RFI/UT
| HIV $\frac{P}{I}$, HB
- (all) CSF for malignant cells
↳ BMA + Bc BMBx
from MBS daycare
- RFL gene testing
- EVA → pending to be done

Plan:
CAL

- (N) in OPD on 25/1/2025 to CBC

gate no 1
viral markers
205
25/1/25
OMM
Dr. Shreshth
Senior Resident
Pediatric Oncology
Department of Pediatrics
AIIMS, New Delhi
My Hospital
meraaspatal.nhp.gov.in

wt \Rightarrow 10.3 kg
Ht \Rightarrow 80.5 cm

Adv

CD/W \bar{c} Prof. R. Sethi.

\downarrow
2/10 BL EORB \rightarrow to
start HDCEV
chemo therapy today

To do (CBC) \rightarrow from
coulter from
day care.

\downarrow
To review CBC and
then give chemotherapy

MCS Daycare

- \rightarrow Coulter
- \rightarrow CBC
- \rightarrow HbF/HbA1c / viral markers
- \rightarrow HIV

- Inj. emiset 1.5 mg IV stat
Inj. dexamethasone 2 mg IV stat

- Inj. VINCRISTINE 0.2 mg
IV slow push (D1)

- Inj. carboplatin 288 mg
in 200ml NS over
1 hour (D1)

- Inj. epirubicin 120 mg in
300ml NS over 2 hours
(D1) & (D2)

- Inj. U5F 50 mg SC
from (D3) \Rightarrow OD x 5 days

last chemo:
Syp. emiset (2mg/5ml) Sml SOS } x
Tab. dexamethasone 4mg 1/2 tab BD } 3 days

(N/V) in OPD on 25/1/2025

To check
coulter prior
to giving
chemo

Truylhelp Verify

HIV \Rightarrow ART (elite)

ANC
9.5 $\left\{ \begin{array}{l} 1090 \\ 5250 \end{array} \right. / 619 \times 10^9 / L^3$
(TLC)

Hbs Ag - NR
Anti-Hbs - 189 - Immune
Anti-HCV Ab - 0.04 - NR

Sumatra
Dr. Shreshtha Kaushik
Senior Resident
Jawahar Institute of Postgraduate
Department of Pediatrics
AIIMS, New Delhi - 110029





NABL Accredited Testing Laboratory
DEPARTMENT OF MICROBIOLOGY
 National HIV Reference Laboratory, Room No-2103
 2nd Floor, Teaching Block, Ph: 011-26594340/3198
 AIIMS, New Delhi- 110029



Certificate No. MC-2472

HIV TEST REPORT FORM

Name and Address of ICTC center: **AIIMS** (form to be filled in duplicate)
 NAME: Surname Singh Middle Name — First Name Balesh
 Gender: M/F/TG M Age: 2 years PID: GCSAICTCDLSOU0012502392 Lab ID 2709297
 Date and time blood drawn: 27/01/25 (DD/MM/YY) 10:50 (HH:MM)

Test Details:

Specimen type : Serum / Plasma / Whole Blood Serum Specimen Quality: Good / Compromised / Outside Collection Good
 Date and time specimen tested: 27/01/25 (DD/MM/YY) 10:50 (HH:MM)

Note:

- Column 2 and 3 to be filled only when HIV 1 & 2 antibody discriminatory test(s) used
- No cell has to be left blank; indicate as NA where not applicable.

Column 1	Column 2	Column 3	Column 4
Name of HIV test Kit	Reactive/Nonreactive (R/NR) for HIV-1 antibodies	Reactive/Nonreactive (R/NR) for HIV-2 antibodies	Reactive/Nonreactive (R/NR) for HIV antibodies
STANDARD-Q	NON REACTIVE	NON REACTIVE	—
Test II:	—	—	—
Test III:	—	—	—

Interpretation of the result: Tick(✓) relevant

- Specimen is Negative for HIV antibodies
 - Specimen is Positive for HIV-1 antibodies
 - *Specimen is Positive for HIV antibodies (HIV 1 and HIV 2; or HIV 2 alone)
 - Specimen is Indeterminate for HIV antibodies. Collect the fresh sample in two-four weeks.
- *Confirmation of HIV 2 sero-status at identified referral laboratory through ART centers.

Name & Signature
 Laboratory Technician

[Signature]
 20/1/25
 -----End of report-----

Name & Signature
 Laboratory In-charge

Dr. DINESH KUMAR DAS, MD (AIIMS), FRCP Edin





अखिल भारतीय आयुर्विज्ञान संस्थान, नई दिल्ली
All India Institute Of Medical Sciences, New Delhi

UHID: 108060720 Sex: Female
Patient Name: Miss. NITIKA Sample Received Date: 03-Feb-2025 18:04 PM
Age: 2Y 3m Department: Paediatrics
Lab Name: Dept of Laboratory Medicine Lab Sub Centre: Smart Lab New OPD Block
Reg Date: 03-Feb-2025 18:04 PM Sample Collection Date: 03-Feb-2025 17:16 PM
Recommended By: Lab Reference No: 2515263089

Sample Details : LH03022502077

Sample Type : Whole Blood

Report

HEMATOLOGY

Test Name (Methodology)	Result	UOM	Reference
Hb (SLS-photometry)	8.10	g/dL	11.0 - 14.0
Hematocrit (Direct Measure)	27.40	%	34 - 40
RBC count (Impedance)	3.93	$10^6/\mu\text{L}$	4.0 - 5.2
WBC count (Fluo. flow cytometry)	15.86	$10^3/\mu\text{L}$	5.0 - 15.0
Platelet count (Impedance)	100.00	$10^3/\mu\text{L}$	200 - 490
MCV (Calculated)	69.70	fL	75 - 87
MCH (Calculated)	28.40	pg	24 - 30
MCHC (Calculated)	28.60	g/dL	31 - 37
RDW-CV (Calculated)	17.80	%	11.6 - 14
Neutro (Fluo. flow cytometry)	59.00	%	30-60%
Lympho (Fluo. flow cytometry)	28.40	%	29-65%
Eosino (Fluo. flow cytometry)	0.30	%	1-4%
Mono (Fluo. flow cytometry)	12.20	%	2-10%
Baso (Fluo. flow cytometry)	0.10	%	0-1%
NRBC	0	%	
Neutro - Abs (Calculated)	9.35	$10^3/\mu\text{l}$	1.5-8.0
Lympho- Abs (Calculated)	4.51	$10^3/\mu\text{l}$	6.0-9.0
Eosino - Abs (Calculated)	0.04	$10^3/\mu\text{l}$	0.1 - 1.0
Mono - Abs (Calculated)	1.94	$10^3/\mu\text{l}$	0.2 - 1.0
Baso - Abs (Calculated)	0.02	$10^3/\mu\text{l}$	0.02 - 0.1

Remarks: Microcytic Hypochromic Anemia with monocytosis. Advice- 1. Reticulocyte count 2. Iron studies 3. Hb HPLC (if clinically indicated, as per results of iron studies) 4. Kindly correlate clinically

-----End of Report-----

Dr. Sudip Kumar Datta
(MD Biochemistry)

Dr. Tushar Sehgal
(DM Hematopathology)

Dr. Suneeta Meena
(MD Microbiology)

Dr Sunil Saroj
03-Feb-2025 19:42



अखिल भारतीय आयुर्विज्ञान संस्थान, नई दिल्ली
ALL INDIA INSTITUTE OF MEDICAL SCIENCES, NEW DELHI
 Department of Microbiology



MC-3267

UHID:	108060720	Reg Date :	15/01/2025 09:26 AM
Patient Name :	Miss. NITIKA	Age :	2 years 3 months 14 days
Sex :	Female	Unit Name :	Unit-I
Department :	DEPT. OF EMERGENCY MEDICINE	Sample Collection Date:	01/02/2025 07:38 AM
Unit Incharge :	Dr. Rakesh Yadav	Lab Sub Centre:	Blood Culture (Microbiology Room No. 2071)
Lab Name:	Microbiology	Report Generated Date:	04/02/2025 12:13 PM
Sample Received Date:	02/02/2025 04:43 PM	Recommended By:	Dr. Rakesh Yadav Emergency HOD
Dept / IRCH No:	20250030001761		
Lab Reference No:	4467		
Ward Name:	DAY CARE PEDS MCH GF		

Sample Details : MBL-010225024 (Blood)

TEST NAME : BLOOD FOR CULTURE

TEST METHOD : CONVENTIONAL/AUTOMATED CULTURE

Culture Result Sterile
 {Conventional Method}:

This is an electronically generated report, authorized signature is not required. The test reports have been authenticated. Partial reproduction of the report is not permitted.

Authorized Signatory



प्रयोगशाला कायचिकित्सा विभाग
DEPARTMENT OF LABORATORY MEDICINE
रुधिर विज्ञान
Hematology

अखिल भारतीय आयुर्विज्ञान संस्थान, अंसारी नगर, नई दिल्ली-110029
All India Institute of Medical Sciences, Ansari Nagar, New Delhi-110029

UHID:	108060720	Sex :	Female
Patient Name :	Miss BALESH SINGH	Sample Received Date :	23/01/2025 08:52 PM
Age :	2 years 3 months 5 days	Department :	Gastroenterology
Unit Name :	Unit-III	Unit Incharge :	
Lab Name:	Hematology	Lab Sub Centre:	Hematology (Ward)
Reg Date :	15/01/2025 09:26 AM	Sample Collection Date:	23/01/2025 06:10 PM
Report Generated Date:	23/01/2025 09:47 pm	Dept / IRCH No:	20250030001761
Recommended By:	Dr. AYUSH AGARWAL	Lab Reference No:	738

Sample Details : HMW-2301250842

Report

Test Name	Result	Comment	Normal Range
Hb(SLS-photometry)	✓ 9.5 g/dL		• 11 - 14 g/dL
HCT (DirectMeasure)	21.1 %		• 34 - 40 %
RBC COUNT (Impedance)	4.48 $10^6/\mu\text{L}$		• 4 - 5.2 $10^6/\mu\text{L}$
T.L.C (Fluo.flowcytometry)	5.25 $10^3/\mu\text{L}$		• 5 - 15 $10^3/\mu\text{L}$
PLATELET COUNT (Impedance)	209 $10^3/\mu\text{L}$		• 200 - 490 $10^3/\mu\text{L}$
MCV (Calculated)	49.4 fL		• 75 - 87 fL
MCH (Calculated)	21.2 pg		• 24 - 30 pg
MCHC (Calculated)	30.5 g/dL		• 31 - 37 g/dL
RDW CV (Calculated)	19.0 %		• 11.6 - 14 %
NEUTRO (Fluo.flowcytometry)	• 20.7 %		• 30 - 60 %
LYMPHO (Fluo.flowcytometry)	68.4 %		• 29 - 65 %
MONO (Fluo.flowcytometry)	8.0 %		• 2 - 10 %
EOSINO (Fluo.flowcytometry)	2.7 %		• 1 - 4 %
BASO (Fluo.flowcytometry)	0.2 %		• 0 - 1 %
NUCLEATED RBC	0.2		
ABSOLUTE NEUTROPHIL COUNT (Calculated)	✓ 1.09 $10^3/\mu\text{L}$		• 1.5 - 8 $10^3/\mu\text{L}$
ABSOLUTE LYMPHOCYTE COUNT (Calculated)	3.59 $10^3/\mu\text{L}$		• 6 - 9 $10^3/\mu\text{L}$
ABSOLUTE MONOCYTE COUNT (Calculated)	0.42 $10^3/\mu\text{L}$		• 0.2 - 1 $10^3/\mu\text{L}$
ABSOLUTE EOSINOPHIL COUNT (Calculated)	0.14 $10^3/\mu\text{L}$		• 0.1 - 1 $10^3/\mu\text{L}$
RDW CV (Calculated)	19.0 %		• 11.6 - 14 %
ABSOLUTE BASO COUNT (Calculated)	0.01 $10^3/\mu\text{L}$		• 0.02 - 0.1 $10^3/\mu\text{L}$

Over All Comment :

Authorised Signatory
Dr.Tushar Sehgal

Verified By
drvani



अखिल भारतीय आयुर्विज्ञान संस्थान, नई दिल्ली
All India Institute Of Medical Sciences, New Delhi

UHID: 108060720 Sex: Female
Patient Name: Miss BALESH SINGH Sample Received Date: 23-Jan-2025 20:09 PM
Age: 2Y 3m Department: Gastroenterology
Lab Name: Dept of Laboratory Medicine Lab Sub Centre: Smart Lab New OPD Block
Reg Date: 23-Jan-2025 20:11 PM Sample Collection Date: 23-Jan-2025 16:05 PM
Recommended By: Lab Reference No: 2515210053

Sample Details : LC2301252218

Sample Type : Serum

Report

BIOCHEMISTRY

Test Name (Methodology)	Result	UOM	Reference
Urea (Urease/GLDH)	19	mg/dL	17 - 49
Creatinine (Jaffe compensated)	0.4	mg/dL	0.2 - 0.4
Uric Acid (Uricase Colorimetric)	2.8	mg/dL	2.4-5.7
Calcium (5-Nitro-5'-methyl-BAPTA)	9.0	mg/dL	8.8 - 10.8
Phosphate (Phosphomolybdate Reduction)	4.8	mg/dL	2.5-4.5
Sodium (ISE (indirect))	139	mmol/L	135 - 145
Potassium (ISE (indirect))	4.3	mmol/L	3.5-5.1
Chloride (ISE (indirect))	103	mmol/L	98-107
Bilirubin (T) (Colorimetric diazo)	0.21	mg/dL	0 - 1
Bilirubin (D) (Diazo Gen.2 Jendrassik-Grof)	0.09	mg/dL	0 - 0.2
Bilirubin (I) (Calculated)	0.12	mg/dL	0 - 0.9
ALT (IFCC without pyridoxal phosphate)	21	U/L	0 - 23
AST (IFCC without pyridoxal phosphate)	41	U/L	<=32
ALP (PNPP, AMP Buffer - IFCC)	189	U/L	142 - 335

Dr. Sudip Kumar Datta
(MD Biochemistry)

Dr. Tushar Sehgal
(DM Hematopathology)

Dr. Suneeta Meena
(MD Microbiology)

Dr Sudip Kumar Datta MD
(Biochemistry)
24-Jan-2025 00:39

SEROLOGY

Test Name (Methodology)	Result	UOM	Reference
HBs Ag (ECLIA)	0.27	COI	< 1.0 Non Reactive ≥ 1.0 Reactive
Anti HBs (ECLIA)	189.00	IU/L	< 10.00 Non Immune ≥ 10.00 Immune
Anti HCV Ab (ECLIA)	0.04	COI	< 1.0 Non Reactive ≥ 1.0 Reactive

-----End of Report-----



अखिल भारतीय आयुर्विज्ञान संस्थान, नई दिल्ली
All India Institute Of Medical Sciences, New Delhi

UHID: 108060720
Patient Name : Miss BALESH SINGH
Age : 2Y 3m
Lab Name: Dept of Laboratory Medicine
Reg Date : 23-Jan-2025 20:11 PM
Recommended By:
Sample Details : LC2301252218

Sex : Female
Sample Received Date : 23-Jan-2025 20:09 PM
Department : Gastroenterology
Lab Sub Centre: Smart Lab New OPD Block
Sample Collection Date: 23-Jan-2025 16:05 PM
Lab Reference No: 2515210053

Sample Type : Serum

Report

SEROLOGY

Test Name (Methodology)	Result	UOM	Reference
Dr. Sudip Kumar Datta (MD Biochemistry)	Dr. Tushar Sehgal (DM Hematopathology)	Dr. Suneeta Meena (MD Microbiology)	Dr Suneeta Meena MD (Microbiology) 24-Jan-2025 00:39

Trulyhelp Verify



अखिल भारतीय आयुर्विज्ञान संस्थान, नई दिल्ली
All India Institute Of Medical Sciences, New Delhi

UHID: 108060720 Sex: Female
Patient Name: Miss. NITIKA Sample Received Date: 04-Feb-2025 00:48 AM
Age: 2Y 3m Department: Paediatrics
Lab Name: Dept of Laboratory Medicine Lab Sub Centre: Smart Lab New OPD Block
Reg Date: 03-Feb-2025 18:04 PM Sample Collection Date: 03-Feb-2025 17:16 PM
Recommended By: Lab Reference No: 2515263095
Sample Details: LC0302252856 Sample Type: Serum

Report

BIOCHEMISTRY

Test Name (Methodology)	Result	UOM	Reference
Urea (Urease/GLDH)	21	mg/dL	17 - 49
Creatinine (Jaffe compensated)	0.2	mg/dL	0.2 - 0.4
Uric Acid (Uricase Colorimetric)	1.8	mg/dL	2.4-5.7
Calcium (5-Nitro-5'-methyl-BAPTA)	9.0	mg/dL	8.8 - 10.8
Phosphate (Phosphomolybdate Reduction)	4.9	mg/dL	2.5-4.5
Sodium (ISE (indirect))	141	mmol/L	135 - 145
Potassium (ISE (indirect))	4.0	mmol/L	3.5-5.1
Chloride (ISE (indirect))	106	mmol/L	98-107
Bilirubin (T) (Colorimetric diazo)	0.10	mg/dL	0 - 1
Bilirubin (D) (Diazo Gen.2 Jendrassik-Grof)	0.07	mg/dL	0 - 0.2
Bilirubin (I) (Calculated)	0.03	mg/dL	0 - 0.9
ALT (IFCC without pyridoxal phosphate)	17	U/L	0 - 23
AST (IFCC without pyridoxal phosphate)	21	U/L	<=32
ALP (PNPP, AMP Buffer - IFCC)	150	U/L	142 - 335
Total protein (Biuret Method)	6.4	g/dL	6.0 - 8.0
Albumin (Bromocresol Green (BCG))	3.8	g/dL	3.8 - 5.4
Globulin (Calculated)	2.6	g/dL	3.0 - 3.7
A/G ratio (Calculated)	1.5		0.8-2.0

-----End of Report-----

Dr. Sudip Kumar Datta
(MD Biochemistry)

Dr. Tushar Sehgal
(DM Hematopathology)

Dr. Suneeta Meena
(MD Microbiology)

Dr Sudip Kumar Datta MD
(Biochemistry)
04-Feb-2025 07:53



ALL INDIA INSTITUTE OF MEDICAL SCIENCES, NEW DELHI

DEPARTMENT OF PEDIATRICS

DAYCARE SHORT ADMISSION

DISCHARGE SUMMARY

Name	Nitika	Gender	male
Age	02 year 03 months	Unit	III
UHID	108060720	DOA	31/01/2025
Diagnosis	B/L EORB	DOD	31/01/2025
Consultant	DR.RACHNA SETH		

Child was admitted for lumbar puncture and bone marrow aspiration/biopsy. After informed & written consent, with all aseptic precautions, Lumbar puncture, Bone marrow aspiration and B/L Bone marrow Biopsy done, uneventfully. Samples [CSF, Bone marrow aspiration (BMA) for cytology, Bone marrow Biopsy for cytology/morphology, PS for cytology] sent. Reports awaited. No complication noted during hospital stay. Vitals stable at the time of discharge

Advice at discharge.

- 1) Strict Hygiene
- 2) Continue OPD medications as advised
- 3) Follow up in Paediatric Unit 1 (New RAK OPD) on (Wednesday, Saturday) as advised
- 4) Danger signs explained

Senior resident

Dr Sanjana/Dr Sharan/
/Dr Shreshtha/Dr. Anu/Dr. Ajan Singh Kardam



Dr. Ajan Singh Kardam
MBBS, MD Paediatrics
Senior Resident
AIIMS, New Delhi

Junior resident

Dr Divyansh/Dr Radhe



नकदी रसीद / CASH RECEIPT
अखिल भारतीय आयुर्विज्ञान संस्थान / ALL INDIA INSTITUTE OF MEDICAL SCIENCES
अंसारी नगर, नई दिल्ली-110029 / Ansari Nagar, New Delhi-110029

दूरभाष / 2658
Phones / 2658

रसीद संख्या / Receipt No.:
जमाकर्ता / Received From:
ओ.पी.डी./यू.एच.सी./आपात स. / OPD / UH/ CAS Days
के नामे / ON ACCOUNT OF

दिनांक / Dated :
रोगी प्रकार / Patient Type :
कक्षा संख्या / Room No. :



SI No.	Service Name	Amount
1	ADVANCE - SHORT ADMISSION	60.00

Printed on 29 Jan 2025 08:44:56 AM

भुगतान का प्रकार / Payment Mode :
रुपये / INR (Rs.) Cash
रुपये शब्दों में / Rs. In Words
60.00 (Including 0.0% GST on room rent only)
Rupees Sixty Only

MR.ASHOK ANAND BILLING

यह कम्प्यूटर द्वारा जारी की गई रसीद है और इसमें हस्ताक्षर और मोहर अपेक्षित नहीं है।
THIS IS COMPUTER GENERATED SLIP AND DOES NOT REQUIRE SIGNATURE AND STAMP

विभाग/DEPARTMENT : Dr. SR Paediatric यूनिट/UNIT : 29/01/2025 08:49 a
यूनिट अध्यक्ष/UNIT HEAD : र्ती की तिथि:/DATE OF ADMISSION : समय/TIME :
परामर्शदाता/CONSULTANT : UHID No. 08060720 DISCHARGE : समय/TIME :
ओ.पी.डी./आपात स./OPD/ CASUALTY NO. :
छुट्टी पर तैनात क.भ.का. स्टाफ का नाम NAME OF CAO STAFF ON DUTY :
इयूटी पर तैनात क.भ.का. स्टाफ का नाम NAME OF CAO STAFF ON DUTY :
SIGN. OF CAO STAFF ON DUTY :

निदान एवं अन्य/DIAGNOSIS & OTHERS

अस्थायी निदान/PROVISIONAL DIAGNOSIS :

पिछली क.भ.सं./PREV.C.R.NO.:

टिप्पणी/REMARKS :

संवेदनाहरण/ANAESTHESIA :

दिनांक/DATE :

समय/TIME :

अंतिम निदान/FINAL DIAGNOSIS :

आंशिक प्रक्रियाएं/OPERATIVE PROCEDURES :

द्वितीयक निदान एवं जटिलताएं
SECONDARY DIAGNOSIS & COMPLICATIONS :

कोड सं./CODE NO.:

मृत्यु का कारण/CAUSE OF DEATH :

शव परीक्षा: हां/नहीं
AUTOPSY: YES/NO

परिणाम: उपचार से ठीक हुए/स्वास्थ्य में सुधार/कोई परिवर्तन नहीं/अनुरोध करने पर छुट्टी की गई/लाभा/फरार/गंभीर/मृत्यु होना।
RESULT: CURED/IMPROVED/UNCHANGED/DISCHARGED ON REQUEST/LAMA/ABSCONDED/WORSE/EXPIRED

वरिष्ठ रेजीडेंट का नाम एवं हस्ताक्षर
NAME & SIGN. OF SR. RESIDENT:

परामर्शदाता के हस्ताक्षर
SIGN. OF CONSULTANT



अखिल भारतीय आयुर्विज्ञान संस्थान / ALL INDIA INSTITUTE OF MEDICAL SCIENCES

अंसारी नगर, नई दिल्ली-110029 / ANSARI NAGAR, NEW DELHI - 110029

फेसशीट (भर्ती एवं छुट्टी रिकॉर्ड) / FACESHEET (ADMISSION AND DISCHARGE RECORD)



संशोधन एवं प्रशिक्षण

FULL Receipt No.: ACCOUNTS-28-25867/202425 AMT. RS. 60

Short Admissions

NON-MLC

Admission Valid till 8 AM

के.पं.सं. CR.No.	H-719148-25	वार्ड/बिस्तर सं. WARD / BED NO.	DAY CARE PEDS MCH GF/SA-30	दिनांक DATE	29/01/2025	समय TIME	08:49 am
नाम/NAME :	MISS. NITIKA	वार्ड/बिस्तर सं. D/O SAJJAN	राष्ट्रीयता/NATIONALITY :	2 Y 3 M 11 D	F	अयु/AGE :	लिंग/SEX :
पिता/पति का नाम / FATHER / HUSBAND NAME :		राष्ट्रीयता/NATIONALITY :	Hindu	धर्म/RELIGION :	Single	वैवाहिक स्थिति/MARITAL STATUS :	
माता का नाम/MOTHER NAME :	Service	क.स्वा.को.सं./सी.सी.एच.एच.सं./EHS NO.	09944946247	संपर्क सं./CONTACT NO. :		आधार सं./AADHAR NO. :	
व्यवसाय/OCCUPATION :		संकेत सं./CONTACT NO. :		राज्य/STATE :		पिन/PIN :	
स्थानीय पता अथवा नजदीकी रिश्तेदार एवं उसका पता LOCAL ADDRESS OR NEXT OF KIN WITH ADDRESS :		स्थायी पता/PERMANENT ADDRESS :		राज्य/STATE :		पिन/PIN :	
	KUSMAURI PIPRA MARORA	LAKHIMPUR KHERI	null INDIA	राज्य/STATE :		पिन/PIN :	

विभाग/द्वारा विवरण/DEPARTMENT DETAILS Paediatrics	Unit-III			
विभाग/DEPARTMENT :	Dr. SR Paediatric	यूनिट/UNIT :	29/01/2025	08:49 a
यूनिट अध्यक्ष/UNIT HEAD :		भर्ती की तिथि:/DATE OF ADMISSION :		समय/TIME :
परामर्शदाता/CONSULTANT :		डिस्चार्ज सं./DISCHARGE :		समय/TIME :
ओ.पी.डी./आपात सं./OPD/ CASUALTY NO. :	UNIT No. 108060720	ड्यूटी पर तैनात के.भ.का. स्टाफ का नाम NAME OF CAO STAFF ON DUTY :		हस्ताक्षर/हस्ताक्षर SIGN. OF CAO STAFF ON DUTY :

निदान एवं अन्य/DIAGNOSIS & OTHERS	पिछली के.पं.सं./PREV.C.R.NO. :		
अस्थायी निदान/PROVISIONAL DIAGNOSIS :			
टिप्पणी/REMARKS :	संवेदनाहरण/ANAESTHESIA :	दिनांक/DATE :	समय/TIME :
अंतिम निदान/FINAL DIAGNOSIS :	ऑपरेटिव प्रक्रियाएं/OPERATIVE PROCEDURES :		
द्वितीयक निदान एवं जटिलताएं SECONDARY DIAGNOSIS & COMPLICATIONS :	कोड सं./CODE NO. :		
मृत्यु का कारण/CAUSE OF DEATH :		शव परीक्षा: हां/नहीं AUTOPSY: YES/NO	
परिणाम: उपचार से ठीक हुए/स्वास्थ्य में सुधार/कोई परिवर्तन नहीं/अनुरोध करने पर छुट्टी की गई/लामा/फरार/गंभीर/मृत्यु होना। RESULT: CURED/IMPROVED/UNCHANGED/DISCHARGED ON REQUEST/LAMA/ABSCONDED/WORSE/EXPIRED			
वरिष्ठ रेजीडेंट का नाम एवं हस्ताक्षर NAME & SIGN. OF SR. RESIDENT :		परामर्शदाता के हस्ताक्षर SIGN. OF CONSULTANT :	

सहमति प्रपत्र/CONSENT FORM

मैं स्वयं/मेरे रोगी के अस्पताल में भर्ती रहने के दौरान उपयुक्त चिकित्सा/शल्यक मूल्यांकन एवं उपचार आवश्यक समझी जाने वाली किसी प्रकार की शारीरिक जांच, नैदानिक मूल्यांकन, बायोप्सी, आधान आदि को निष्पादित करने के लिए एतद्वारा, सहमति देता/देती हूँ।

I hereby give my consent for the performance of any physical examination, diagnostic evaluation, Biopsy, Transfusion etc. that may be deemed necessary in the proper medical/surgical evaluation & treatment for me/my patient while the patient is in Hospital.

शिक्षण एवं अनुसंधान हेतु नैमिक चिकित्सा उपचार के भाग के रूप में एकत्रित किए गए आंकड़ों/प्रतिबिंबों/जैविक नमूनों के बचे हुए भागों के प्रयोग हेतु सहमति CONSENT FOR USE OF REMNANT DATA/IMAGES/BIOSPECIMENS COLLECTED AS PART OF ROUTINE MEDICAL CARE FOR TEACHING & RESEARCH

मैं, एतद्वारा, किसी भी प्रकार की सामग्री (आंकड़ें, प्रतिबिंबों, जैविक नमूनों/सूक्ष्म जीवविज्ञान नमूनों), जो मेरे/मेरे बच्चे के/आश्रित के नैमिक उपचार (जांच, निदान, उपचार, इलाज आदि) के भाग के रूप में एकत्रित किए गए हैं तथा जिनकी इस प्रकार की उपयोगिता नहीं है और जिसका प्रयोग शिक्षण एवं अनुसंधान हेतु अखिल भारतीय आयुर्विज्ञान संस्थान, नई दिल्ली द्वारा भंडारित/संग्रहित/नष्ट करने के लिए किया जाएगा, के प्रयोग हेतु सहमति देता/देती/नहीं देता/नहीं देती हूँ। मैं समझता/समझती हूँ कि इस सामग्री का प्रयोग संस्थान की नीति समिति के विधिवत रूप से अनुमोदन से, उनके द्वारा स्वीकृत दिशा-निर्देशों एवं मानक प्रक्रियाओं के अनुसार किया जाएगा। मुझे न तो भविष्य में संपर्क किया जाएगा और ना ही मुझ पर इस संबंध में किसी प्रकार की वित्तीय वचनबद्धता होगी।

I hereby give/ do not give my consent for the use of any remnant material (data, images, biological specimens/microbiology specimens) that have been collected as a part of my/my child's/ward's routine care (investigation, diagnosis, treatment, management etc.) and that do not have any further utility for such care but would be otherwise stored/archived/discarded to be utilized by the All India Institute of Medical Sciences, New Delhi for teaching and research. I understand that this material will be utilized in accordance with the accepted guidelines, standard procedures and duly approved by the Institutional Ethics Committee. I may neither be contacted in future nor will there be any financial commitment in this regard.

रोगी के हस्ताक्षर (रिश्तेदार केवल तभी जब रोगी हस्ताक्षर करने में असमर्थ हो)

Signature of Patient _____

(Relative only if patient is unable to sign.)

नाम (स्पष्ट शब्दों में) / Name (Capital letters) _____

पता/ Address _____

संबंध/Relationship _____

रिश्तेदार/गवाह के हस्ताक्षर Relative/Witness Signature _____

नाम (स्पष्ट शब्दों में) Name (Capital letters) _____

पता/ Address _____

परामर्श के विरुद्ध छुट्टी लेने पर जिम्मेदारी से मुक्ति

RELEASE FROM RESPONSIBILITY FOR DISCHARGING AGAINST ADVICE

मैं, उपचार कर रहे चिकित्सक की सलाह के विरुद्ध अ.भा.आ.सं. अस्पताल, नई दिल्ली से रोगी को ले जा रहा हूँ/छुट्टी ले रहा हूँ। मुझे इसमें सम्मिलित जोखिम के बारे में सूचित कर दिया गया है एवं मैं, एतद्वारा, उपचार कर रहे डॉक्टर एवं अस्पताल इस प्रकार की छुट्टी के परिणामस्वरूप हो सकने वाले किसी प्रकार के दुष्प्रभावों की जिम्मेदारी से मुक्त करता/करती हूँ।

I am leaving/taking away the patient from the AIIMS Hospital, New Delhi against the advice of the Attending Physician. I acknowledge that I have been informed of the risk involved and hereby release the Attending Physician and the hospital from all responsibility for any ill effects which may result from such discharge.

रोगी के हस्ताक्षर (रिश्तेदार केवल तभी जब रोगी हस्ताक्षर करने में असमर्थ हो)

Signature of Patient _____

(Relative only if patient is unable to sign.)

नाम (स्पष्ट शब्दों में) / Name (Capital letters) _____

पता/ Address _____

संबंध/Relationship _____

रिश्तेदार/गवाह के हस्ताक्षर Relative/Witness Signature _____

नाम (स्पष्ट शब्दों में) Name (Capital letters) _____

पता/ Address _____


180

(REVISIT)

Sample Profile

STP pHox Ultra
 Printed: 01/02/2025 05:52:20 AM
 Analyzed: 01/02/2025 05:50:03 AM
 Analyzer ID: Z31A17130N

अखिल भारतीय आयुर्विज्ञान संस्थान, नई दिल्ली-110029
 ALL INDIA INSTITUTE OF MEDICAL SCIENCES, NEW DELHI - 110029
 आपातकालीन विभाग



Barometer 723.5 mmHg
 Sample Type Arterial
 Operator 123456
 Releaser: auto
 Patient ID: 108060720
 Patient Name: NITIKA

EPT. OF EMERGENCY MEDICINE)
 25/030/0011151 दिनांक DATE: 01/02/2025

समय TIME: 04:13:38 AM
 NON-MLC

Patient ID 108060720
 Sex Female
 AGE
 First Name
Other Flags
 COOX Insufficient Sample
Comments

आयु AGE : 2 years 3 months 14 days लिंग/SEX : F
 गली / मुहल्ला STREET/ PIPRA MARORA
 MOH: 261506
 पिन PIN: 9994946247
 दूरभाष सं. PHONE NO: Paediatrics Emergency
 स्थान Location: Paediatrics Emergency
 Criticality: Red / Yellow / Green

Test	Value	Units	Flags
pH	7.391	✓	
pCO2	35.8	mmHg	
pO2	39.2	mmHg	
Na+	138.1	mmol/L	✓
K+	3.65	mmol/L	✓
Cl-	101.6	mmol/L	✓
Ca++	1.19	mmol/L	
Glu	95	mg/dL	
Lac	2.7	mmol/L	✓
BUN	0.4	mg/dL	
Creat	23.0	mmol/L	
TCO2	1.19	mmol/L	
nCa	14.5	mmol/L	
Gap	73.9		
SO2%	-3.2	mmol/L	
BE-ecf	-1.9	mmol/L	
BE-b	22.3	mmol/L	
SBC	21.9	mmol/L	
HCO3-	1.5		
RI	18.7	mmHg	
PO2/FIO2	98.5	mmHg	
A	59.2	mmHg	
A-aDO2	0.4		
a/A			

BP mmHg RR /min spO2 %
 Cold c/o - EORS x 7 days.
 Cough x 7 days.
 New (Temp documented 102.6 on 1 day)

Trulyhelp Verify

SpO2 on Room air... 99% HR - 104g UC ant Pentagon Irradiation RR: 150/min CFT: 43 secs. BP: 106/70 mmHg Peripheral pulse: Poor/Good Central pulse: Poor/Good Skin temp: Warm/cool Others	Disability GCS: 15/15 Pupil size: /min Pupillary Reactions: Motor activity: Normal & Symmetrical/ Asymmetrical/ Posturing/Flaccidity/Seizure Blood Sugar: mg/dl Exposure: Temp: Colour: Normal/pallor/cyanosis/ mottled Any other skin lesions:
---	---

Diagnosis EORS / ? AN (Focus - Respiratory)
 was (fa - temp 7600F) 1/2 4:30 AM
 100.5°F
 VBY 6am
 12/25/25 7/10/25
 x-ray chest
 Monitor vitals
 chating
 10mg iv 24rdly
 100mg iv 12rdly for 1st 3 doses
 Piptaz 1gm iv 8rdly
 Yecop lanni 100mg iv 12rdly for 1st 3 doses
 10mg iv 24rdly

1/2/25
7am.

c/s/B Peds onco SR oncall

c/o Familial RB/B/L EORB.

↓ BMA + BX + CSF → 31/1/25

HIDCEV 23/1 - 24/5 ; completed 4 CSF on 29/1/25

c/o cough/coryza x 5 days. → on cetirizine
low grade fever 100.5° at night

No rash/loose stools/respiratory distress/mucositis

o/e Afebrile
HR = 112/min
RR = 32/min
mild Ica (+)
SpO₂ = 98%.

o/I VBG - (N)
lac → 2.7

CXR - (R) perihilar infiltrates (+)

7.8 / 374 / 1.19L
210

No nasal flaring
Chest - clear → no wheezes/crpts.
CP/PO +1/+1.

Di:- FN/?LRTI

plan (wt = 10 kg)

PET → 20/2/25
not done
on 29/1/25
1/1/0 (+) chemo.

Notes

- ✓ Syp PCM (5ml/250mg) 3ml so
- Fever charting
- Blood c/s to send.
- Inj PIPTAZ to continue
- Inj AMIKACIN 150mg IV OD
- D/C Inj Teicoplanin
- Inj GLSF 50mg s/c OD.
- ✓ Syp Cetirizine (5ml/5mg) 2.5ml
H/S x 5 days x — o
- N/V 03/02/25 at 2pm POC
for FN urine

Shunni
in POC.

- Alternate day → for FN urine
- Dexamethasone 1mg IV qd

अखिल भारतीय आयुर्विज्ञान संस्थान, नई दिल्ली-110029

ALL INDIA INSTITUTE OF MEDICAL SCIENCES, NEW DELHI-110029

नाम Name	उम्र Age	लिंग Sex	वैवाहिक स्थिति Marital Status	यू.एच.आई.डी. नं. UHID No.
MITAKA	24	F		10P660720
सेवा Service	वार्ड Ward	बेड Bed	व्यवसाय Occupation	धर्म Religion

ALL INJECTIONS TO BE INITIALED BY PERSON ADMINISTERING

Date & Time	Medication & Treatment	Diet	Observation by the Nurse
	1/2/25		
6AM	inj pcm 150mg iv sos		
6AM	inj piper 2 gm iv 2pk		
6AM	inj fero 100mg iv 0,12,4		
	flb		
	100mg op		
8AM	Inj - GCSP 20mg s/c op		
8AM	Inj - Amikacin 150 mg iv op		

Truhelp Verify



GOYAL MRI & DIAGNOSTIC CENTRE

B-1/12, SAIDAROUNG ENCLAVE, NEW DELHI - 110029
Phone : 011-40771234, 26107559 E-mail : goyalmri@yahoo.com

Dr. Ankur Gadodia
MD (AIIMS), DNB, FRCR

Dr. Pranay R Kapur
MBBS, DNB

MAST. BALESH SINGH, 2 YRS / M

UID: 01.25.692

20.01.2025

M.R. OF THE BRAIN AND ORBITS WITH CONTRAST

Axial T1, DWI and FSE T2 weighted scans of the brain were studied and these were correlated with coronal T2, fat sat T1 & T2 weighted scans including both orbits. Additional T1 weighted axial, coronal & sagittal scans were obtained following administration of contrast (10mL Omniscan). No immediate adverse contrast reaction was noted.

Left globe is increased in size. Large mass lesion measuring 25 x 22 x 27 mm is seen involving the anterior and posterior chamber of the left globe. Lesion displays high intense signal on both T1 and T2 weighted images. There is extraocular extension of the lesion into the retroocular fat. Left optic nerve is unremarkable. There is heterogeneous enhancement following administration of contrast.

Right globe is normal in size. Multiple small focal lesions are seen in the posterior chamber of the right globe, largest measuring 3 x 10 mm. No extraocular extension is seen. Right optic nerve is unremarkable. There is subtle enhancement following administration of contrast.

The optic chiasm, infundibulum and pituitary gland do not show abnormality.

Cerebral and cerebellar parenchyma is unremarkable. No acute infarct is seen on diffusion weighted images.

Bilateral basal ganglia and thalami are normal in signal intensity.

The corpus callosum and skull base are normal. No midline shift is seen. No acute intracerebral hemorrhage.


Posterior fossa and brainstem are unremarkable. Skull base arteries demonstrate normal flow void.

Paranasal sinuses are unremarkable.

IMPRESSION:

Findings are suggestive of bilateral retinoblastoma (L>R) with extraocular extension on the left side. Bilateral optic nerves are unremarkable.

Clinical and histopathological correlation is necessary


DR. ANKUR GADODIA
MD (AIIMS), DNB, FRCR (UK)

This is a professional opinion and not the diagnosis. Findings should be clinically correlated.

Facilities Available : 3.0 Tesla GE Pioneer MRI, 32 Slice CT Scan, Bone Densitometry (DEXA), Ultrasound with Color Doppler, Digital X-Ray, Echocardiography, ECG, PFT, EEG, NCV, EMG, Pathology Lab (NABL & NABH Accredited)

A Life Of Dignity For All



Patient Details

Name : Balesh Singh (Nitika)

Age / Gender : 2y / R

Father's Name : Sajjan

Address : Lakhimpur, U.P.

Contact No : 9994946247

POC / PCSC No.: 31/25-

Diagnosis: EORB

Remarks :

HIV Status

HBV 0

PICC Line Care

अगर आपके बच्चे को PICC Line Care लगी हुई है तो डे केयर के ड या नर्स से जरूर संपर्क करें।

Truylhelp Verify

Counselling done

- 2x Bedtime gargle
- 8 1/2 bath.
- Personal hygiene
- Blood donation
- sick card given
- Darger sign explained
- Accusation

Diagnostic Work UP & Risk Stratification

do white eye reflex in BL eye
since x 2 years

do protrusion of ⊙ eye x 10 days

H/O RB in father (underwent enucleation in childhood)

MR 1 → RL discussion → BL intraorbital part of ON involved
optic chiasma → ⊙

US 4 → ⊙ mass @ Post pole ± high spike calcification + ut.
⊙ whole globe mass filled, high spikes slo
calcification

Metastatic w/o:

PET scan → 29/1/25

BMA + BL BMBx dff → 31/1/25

CSF. dff → 31/1/25

Trulyhelp Verify

enrolled → iv arm

do BL EO RB

Name of treatment protocol

received 1st HD-CEV from 23/1 - 24/1/25

27/1/25

Consultations

Polymerase chain reaction:

- ↳ RBI gene testing
- ↳ metatatic workshop → expedite.
- ↳ RT registration.

Adv

- RBI gene testing

- PET scan → d/f 29/1/25

- BMA + BLC + BMBx CSF for metatatic cell } → 31/1/25

(*) - syp. ceftriaxone (5mg/sml) 2-5ml HS x 5 days

- Iry (50mcg SC OD x 5 days)

(D1) - 25/1 ✓

(D2) - 26/1 ✓

(D3) - 27/1

(D4) - 28/1

(D5) - 29/1

- (DL) HIV report

(*) - syp. septran (40mg/sml) sml alternate day

- oral care / sitz Bath

- (Nlv) in OPD on 1/2/2025
CBC / KFT / UFT

- RT registration

Prunty



To
cousins,

27/1/25

Kindly consider RBI gene testing for the patient.

Thank You,

1
Suresh
Dr. Shreshtha Kausik
Senior Resident
DM. Pediatric Oncology
Department of Pediatrics
AIIMS, New Delhi-110029

3/2/25

B/L CORB
Chiasma (M)

① metastatic w/pt. pending done → reports pending.

② received C#1 HPT → 23/1, 24/1.

③ had FN post C#1.

↓
✓ 40 cold/cough (F)

✓ 40 perilar infiltrates (F)

likely viral

- currently asymptomatic.

④ Per dated → 20/2/25.

Adv,

① q/c Blood & report

② q/c BMA - PS, CSF & BMBx report.

③ to continue inj. Pip taz / Amikacin
from ~~inpatient~~ ^{ambulatory} basis

④ inj. GCSF 50mg sc tid till ANC recovery.

⑤ PN review from MCB Daycare.

⑥ 10/2 = CAC/PT/LA

3/2.
CAC/PT/LA.

Trulyhelp Verify

Satyendra

LC0302252856 108060720

LH03022502077 108060720

NITIKA

5/2/25

FN review

- afebrile
- no active complaints
- PCR - negative

8.1 $\frac{15,860}{9350}$ (1. lac)

Blood $\frac{1}{3}$ - sterile

Adv.

- STOP iv antibiotics
- STOP inj. G-CSF

Trulyhelp Verify


- Syp. Cetrizine (1mg/5ml) 2 ml 45. \times 0
 - Syp. Paracetamol (2mg/5ml) 5ml 508. 2 ml

- cough signs explained

- N/C 8/2/25 E CBC/RN/UR

Satyendra
Sr.

⊖ old Tobramycin 10 QID



8/02/2025

B/L EORB

planned for NACT (LT → EN → RT)

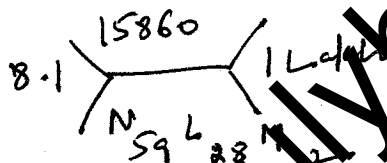
received ① cycle of HDCEV (23/1/25 - 24/1/25)

metastatic w/v

PET: redated to 20/2/2025

BMA + BMB
CSF } done on 31/1/25
reports awaited.

HIV: NR



$WBC = 21/0.2$
 $CRP = 9.0/4.9$
 $AST/ALT/ALP = 21/17/150$

to get PET done before #2 HDCEV

2) (RT registration)

3) PET dated on 20/02/2025

NPO: 9am, Day 1

4) N/V on 22/02/25

CBC
LFT
RFT

~~BMA + BMB~~
Reports

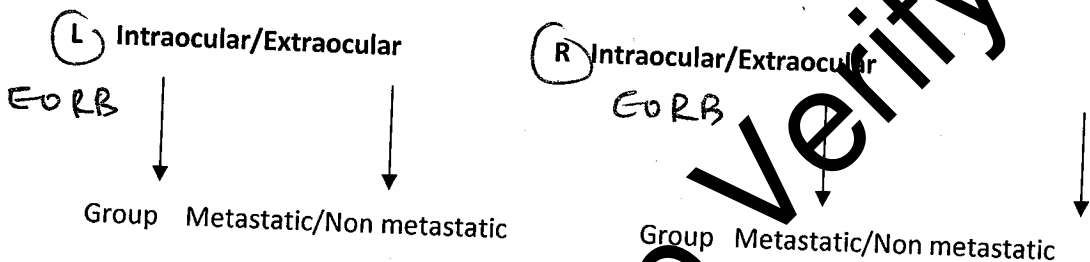
Dr. [Signature]

All India Institute of Medical Sciences, New Delhi.

Division of pediatric Oncology

TREATMENT PROTOCOL FOR RETINOBLASTOMA

Name..... Ballesh Singh Father's name.....
 history..... father Age..... 2y 3m Sex..... F POC NO..... family
 Squint/white reflex/diminishes vision/red eye/watering of eyes/Proptosis
 Others.....
 Unilateral/bilateral.....
 MT..... HBsAg..... HIV.....



Baseline workup/Investigations

USG..... Ⓟ mass @ Post pole - high spike calcification +nt
Ⓟ whole globe filled mass, no fo contents distinguished
high spikes/lo calcification +nt
 EUA.....

Indirect Ophthalmoscopy

CT/MRI date & report

BL EORB (BL intraorbital part of ON involved)
optic chiasma → (N)

Review of imaging at radioconference: Yes/No

↓
to BL EORB

Hb.....TLC.....Platelet.....ANC.....
 SGOT/SGPT/S.Bil/SAP.....
 MT..... HBsAg..... HIV.....

Truymed Verify

ब. रो. वि. कार्ड
O.P.D. Card



अनुभाग व दिन
Section and Day VI
बुधवार व शनिवार
Wednesday & Saturday

कमरा नंबर
Cabin No.



UHID: 108060720
ABHA:
Dept No: 20250300011151

संख्या / Queue 0
कमरा / Room: Emergent
Unit-I
Paediatrics Emergency

Dr. Praveen Aggarwal
MON, TUE, WED, THU, FRI, SAT,
SUN

Registration time:
01/02/2025 04:13:38 AM

NITIKA

D/O SAJJAN
2Y 3M 16D / F
KUSMAURI, PIPRA MARORA, LAKHIMPUR
KHURI, UTTAR PRADESH, Pin: 281508, INDIA
Mob: 9994946247 General Rs. 0
null

स्टेशन का एकक
Tandon's Unit

पता
Address

Bareshsingh

दिनांक DATE	निदान DIAGNOSIS
	Ⓜ 2 RB

उपचार Treatment

3/2/25

CSIS SR Sonya n... unit VI

- Ⓜ circumferential irregular enhancement of walls seen
- Ⓜ no schell Retinal thickening
- Ⓜ globular larger in size
- Ⓜ 12 hypo intense lesion 2 closed funnel (Subretinal projection) of central choroidal
- Ⓜ no no mass inside (signal low)
- Ⓜ ? Bleed Extracocular

कृपया इस कार्ड को सुरक्षित रखें तथा अस्पताल में दिखाने के समय हर वक्त साथ लायें।
Kindly keep this Card safely and bring it on your follow-up visits.

1. धूम्रपान निषेध 2. कूड़ा कर्कट केवल कूड़ेदान में ही डालें 3. थूकिये नहीं
1. No Smoking 2. Use Dustbin 3. No Spitting

B/L NO extracerebral / optic nerve involvement

- Ⓚ Enhancement of pterygoid thickening
- Ⓚ enhancement outside scleral wall
- Ⓚ mass extend across optic nerve

Ⓚ Enhancing mass extend behind sclera (not along O. Nerve.)

• pineal gland normal

DIF Study SUV
L1 tamoxifen

1 cycle chemo given.

patient has been 3 days on IVAB
 (Flupl + HADU clearance for Study SUV date)
 (Old ONCO -> 1428)
 dpm Mon/Wed

→ Paeds Oncology
 con-referral for opinion
 start IV
 Chemo.

(d10/209/211)
 Dr Adib / Piy Rachna
 Wed/Sat

नेत्र ईश्वरीय सर्वश्रेष्ठ उपहार है जिनका मनुष्य जीवन में दान करना परमश्रेष्ठ है।
 इनकी पूर्ण रक्षा कीजिए ताकि ये अपनी रक्षा कर सकें।
 Eyes are God's most precious gift to man kind and eye donation is the most noble deed.
 Take full care of them so that they can take care of you.

CKID - 98964

ब. रो. वि. कार्ड O.P.D. Card



अनुभाग व दिन
Section and Day VI
बुधवार व शनिवार
Wednesday & Saturday

कमरा नंबर
Cabin No.

डा. राजेन्द्र प्रसाद नेत्र विज्ञान केन्द्र
नया राधा आश्रम सं. नई दिल्ली-110029



UHID: 108060720
ABHA:
Dept No: 20250050006044
Clinic No: 2025/R B/22

संख्या / Queue 3
कमरा / Room: 142
Unit-VI
Retinoblastoma

NITIKA

Dr. SR/JR RB -VI- R.142B

D/O SAJJAN
2Y 3M 10D / F
MUSMAURI, PIPRA MARORA, LAKHIMPUR
KHURI, UTTAR PRADESH, Pin:281506, INDIA
Mob: 9984946247 General Rs. 0
New Patient

Registration time:
15/01/2025 12:58:24 PM

का टंडन का एकक
Nitika Tandon's Unit

आयु Age	पता Address
5y	Lakhimpur, Uttar Pradesh

दिनांक DATE	निदान DIAGNOSIS
15/1/25	<p>उपचार Treatment C/O/W Dr Sumit in New oncology Clinic</p> <p>1. MRI done outside (12/1/25) sp. left eye globe by bulky and completely replaced by ill defined irregular altered signal intensity mass lesion (28X27X21 mm), infiltrating into lateral rectus muscle + IM soft tissue edema, posterolymmal extension in retrobulbar fat & partial involvement of optic nerve near its attachment of disc shows altered signal intensity and proptosis of eye glob → thickening of optic nerve & encasement of perineural CSF space</p> <p>2. Eye globe minimally enlarged → nodular altered signal intensity soft tissue (3-4mm upto lymts 16x17mm) + do closely abutting optic nerve</p>

कृपया इस कार्ड को सुरक्षित रखें तथा अस्पताल में दिखाने के समय हर वक्त साथ लायें।
Kindly keep this Card safely and bring it on your follow-up visits.

- 1. धूम्रपान निषेध 2. कूड़ा कर्कट केवल कूड़ेदान में ही डालें 3. थूकिये नहीं
- 1. No Smoking 2. Use Dustbin 3. No Spitting

USG → mass at post pole c high spike. Cont ⊕
 whole globe filled c mass
 no intravascular contents distinguished
 high spikes s/o calcification ⊕.

→ Paeds oncology consult sent

→ HJLP c reports for NRC (53) 20/1/25
 on Monday. 10:00 AM.

→ Date for (EUA) after NRC

29/1/25
 did not
 come as
 advice
 31/1/25
 the next
 Monday
 (53) 10 AM
 NRC report
 for NRC

→ Paed sonography
 Dr. Raelva / Dr. Heityer / Dr. Jogleish

(EUA)

210/20.5 (2nd floor, New RAK)
 (Wed/Sat. 9:00 AM)

Date for EUA
 PNC
 representation

Verify

22/1/2025
 Dr. NEIWETELOMI
 Professor

नेत्र ईश्वरीय सर्वश्रेष्ठ उपहार है जिनका मनुष्य जीवम में दान करना परमश्रेष्ठ है।
 इनकी पूर्ण रक्षा कीजिए ताकि ये अपनी रक्षा कर सकें।
 Eyes are God's most precious gift to man kind and eye donation is the most noble deed.
 Take full care of them so that they can take care of you.

ब. रो. वि. कार्ड
O.P.D. Card

डा. राजेन्द्र प्रसाद नेत्र विज्ञान केन्द्र
अ. भा. आयु. सं., नई दिल्ली-110029

Dr. Rajendra Prasad Centre
A.I.I.M.S., New Delhi-110

यू.एच.आई.डी. संख्या
UHID No.

रोगी का नाम
Name of the Patient

दिनांक
DATE

निदान
DIAGNOSIS



नेत्र अमृत्यु उपहार है
जो आप ही दे सकते हैं

VI/BB/22/25

अनुभाग व/दिन
Section and Day VI
बुधवार व शनिवार
Wednesday & Saturday

कमरा नंबर
Cabin No.



UHID: 108060720
ABHA:
Dept No: 20250300011151

संख्या / Queue 0
कमरा / Room: Emergent
Unit-I
Paediatrics Emergency

NITIKA

Dr. Praveen Aggarwal

D/O SAJJAN
2Y 3M 16D / F
KUSMAURI, PIPRA MARORA, LAKHIMPUR
KHERI, UTTAR PRADESH, Pin:261508, INDIA
Mob: 9984946247 General Rs. 0
null

MON, TUE, WED, THU, FRI, SAT,
SUN



Registration time:
01/02/2025 04:13:38 AM

VAK / NOT
cooperative

उपचार Treatment
Clo white capsules @ 3marbles
of age

Outside diagnosed

Bln

Retino blastoma

Trulyhelp Verify

Fixed dilated pupil
i ant scleral extension
i hyphema (+)

Distorted ant. segment
i ant staphyloma (+)

कृपया इस कार्ड को सुरक्षित रखें तथा अस्पताल में दिखाने के समय हर वक्त साथ लायें।

Kindly keep this Card safely and bring it on your follow-up visits.

- धूम्रपान निषेध
- कूड़ा कर्कट केवल कूड़ेदान में ही डालें
- थूकिये नहीं

1. No Smoking

2. Use Dustbin

3. No Spitting

2A
MSG
RB

① Intracocular high spikes
note at 2PB (hr 6.9)
= mild amplitude spikes in VC
?? needs
(wides gain)

② mod amplitude spikes noticed
no ocular structure identified
(wides gain)

142
@ 2PM
today

#7

RB / Ono clinic
registration
today
15/1/25
Print of

Trulyhelp Verity

Clear

नेत्र ईश्वरीय सर्वश्रेष्ठ उपहार है जिनका मनुष्य जीवन में दान करना परमश्रेष्ठ है।
इनकी पूर्ण रक्षा कीजिए ताकि ये अपनी रक्षा कर सकें।
Eyes are God's most precious gift to man kind and eye donation is the most noble deed.
Take full care of them so that they can take care of you.



